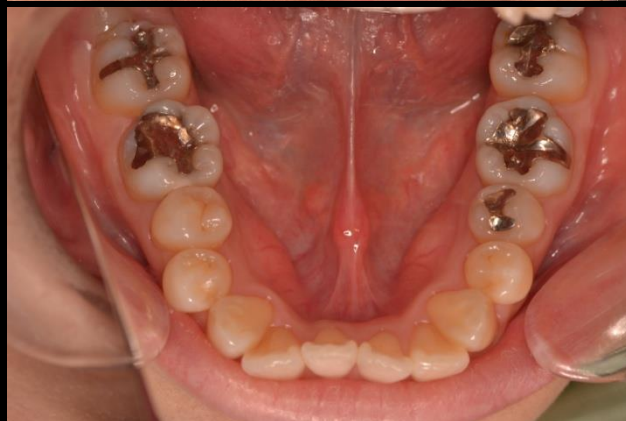
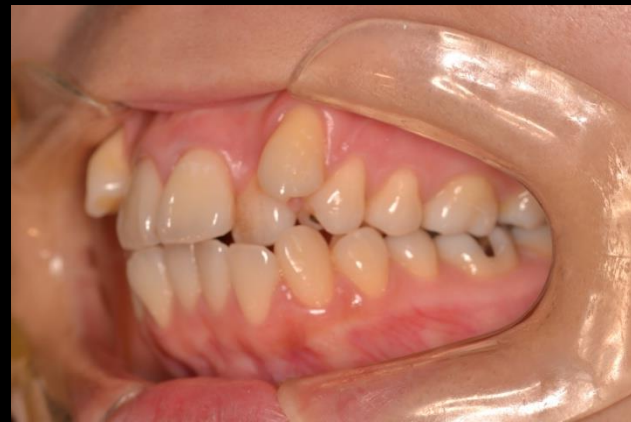
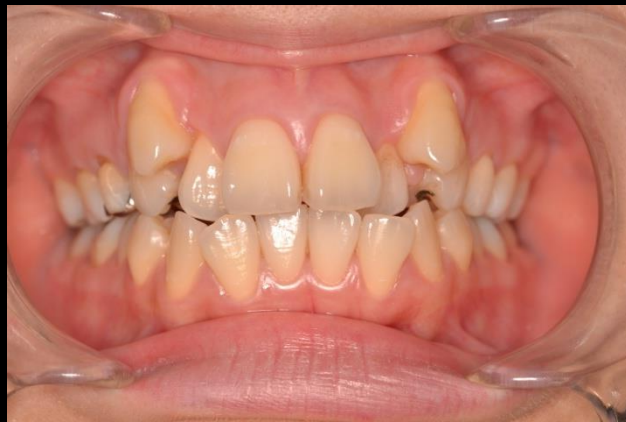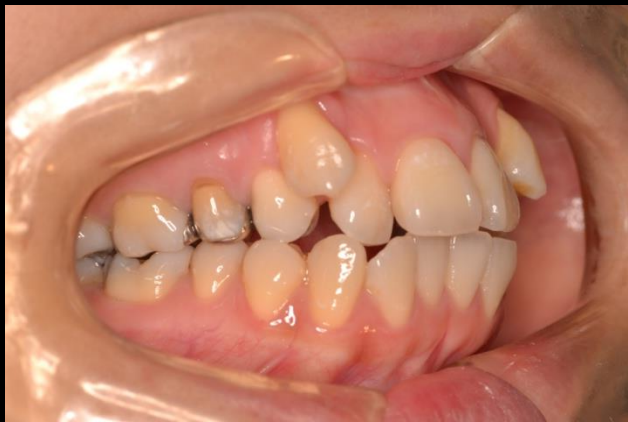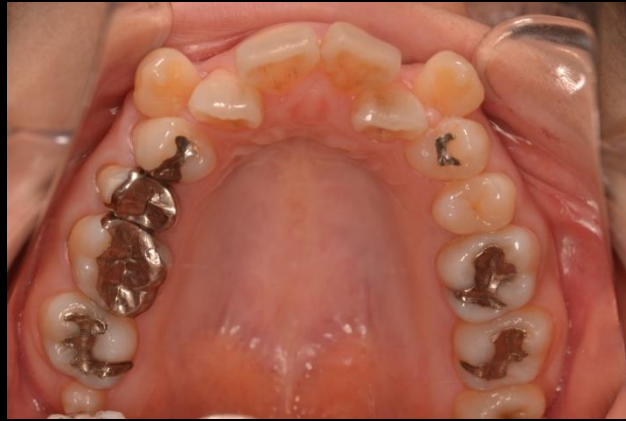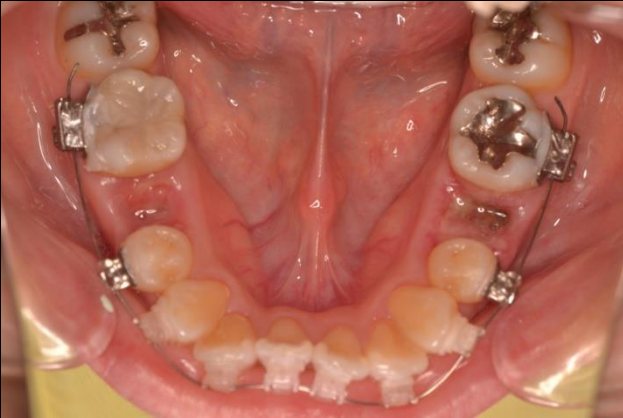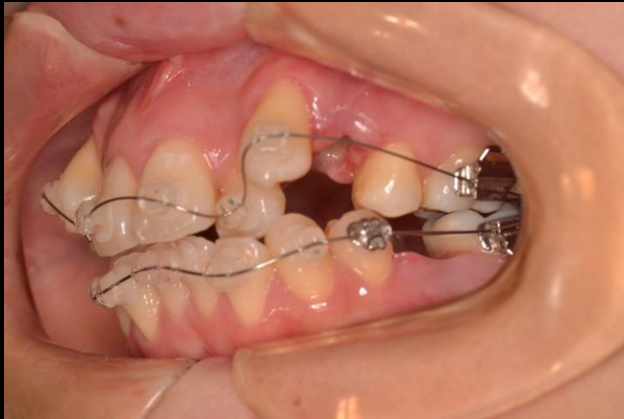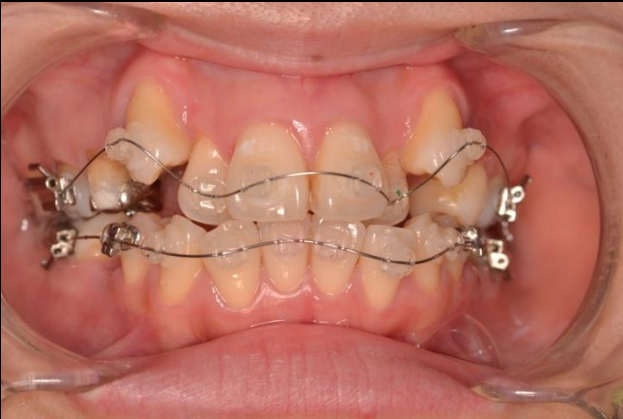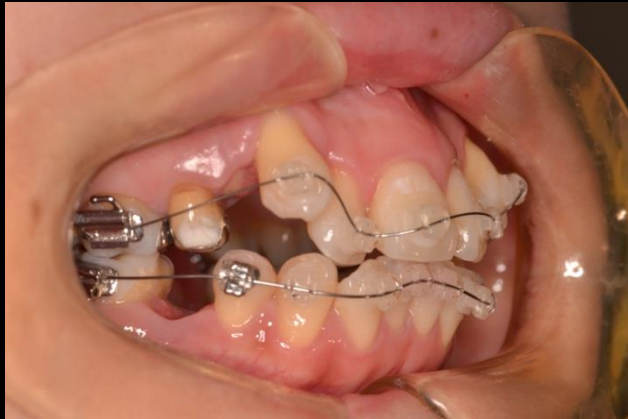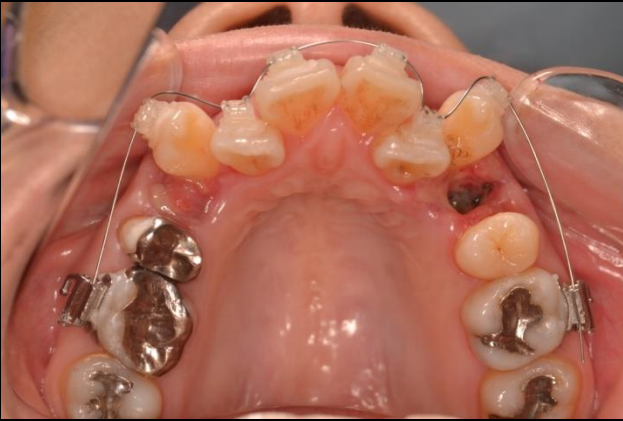症例 1 : 22歳 女性 (前歯の叢生)

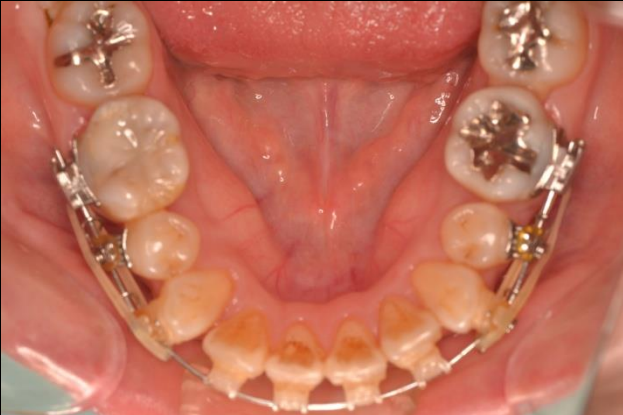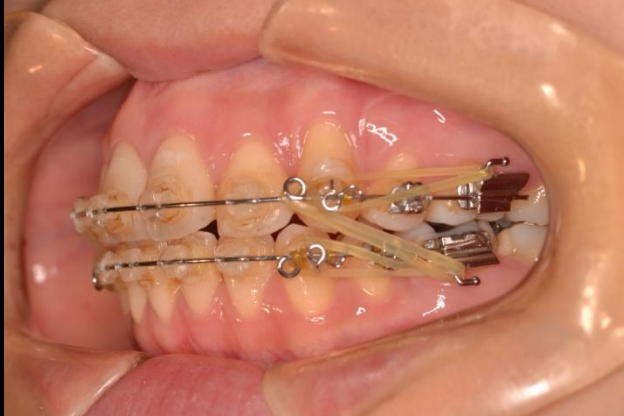
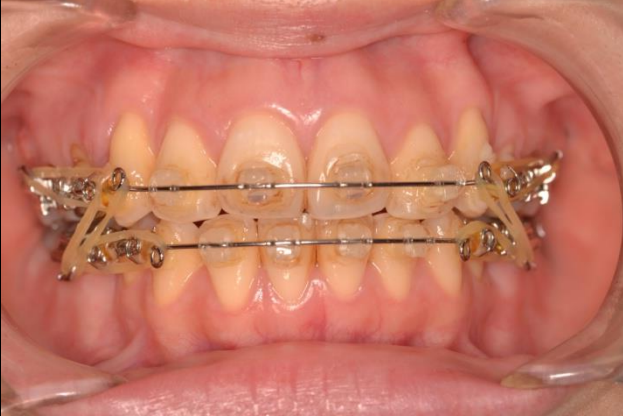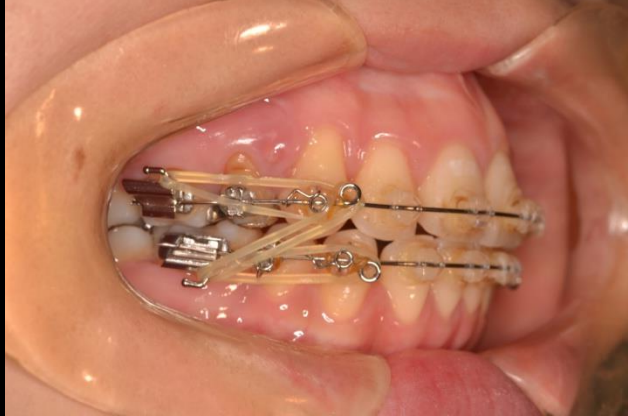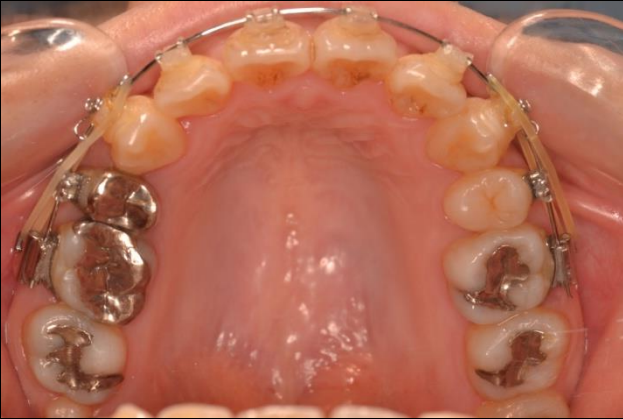初診時口腔内写真



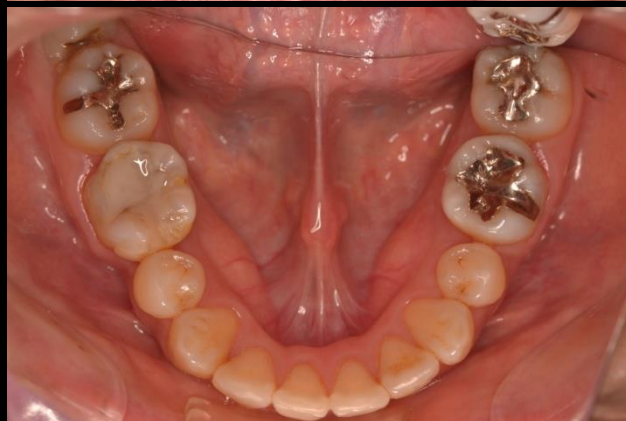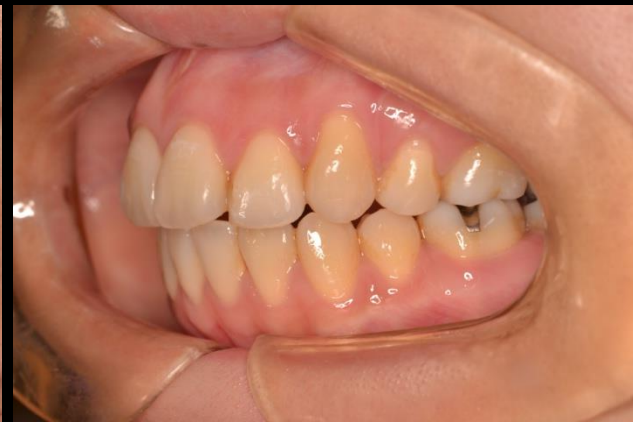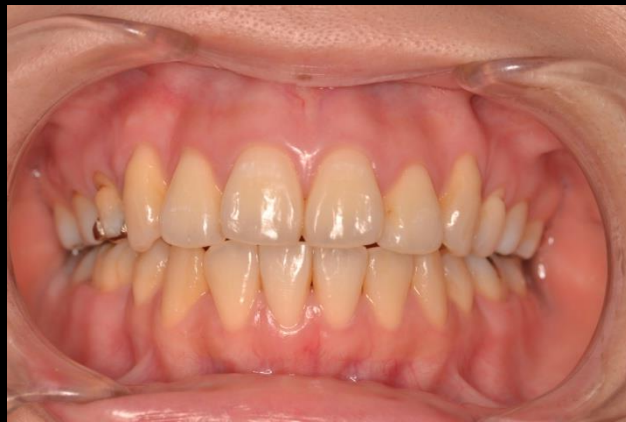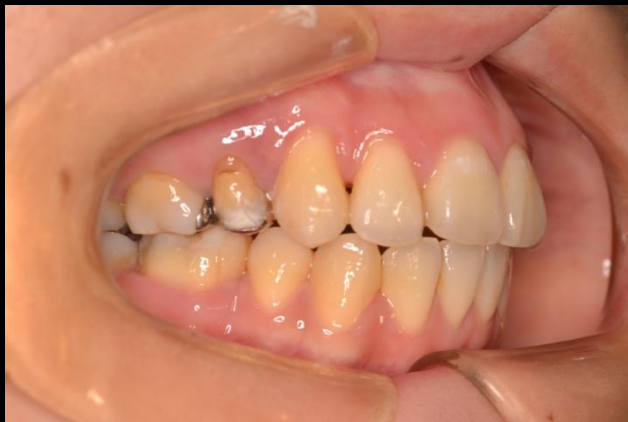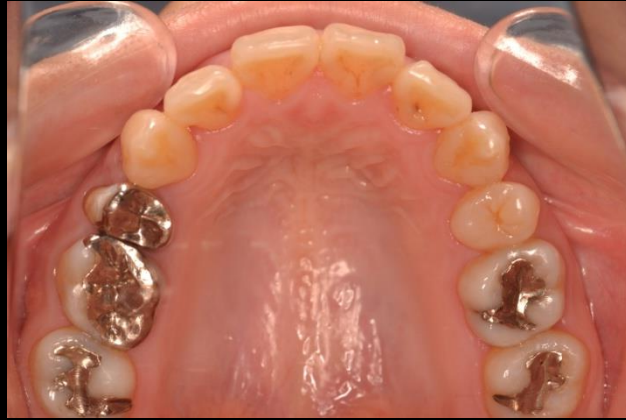Stage I Step 1 012 NiTi



Stage II Step 2



矯正終了直後

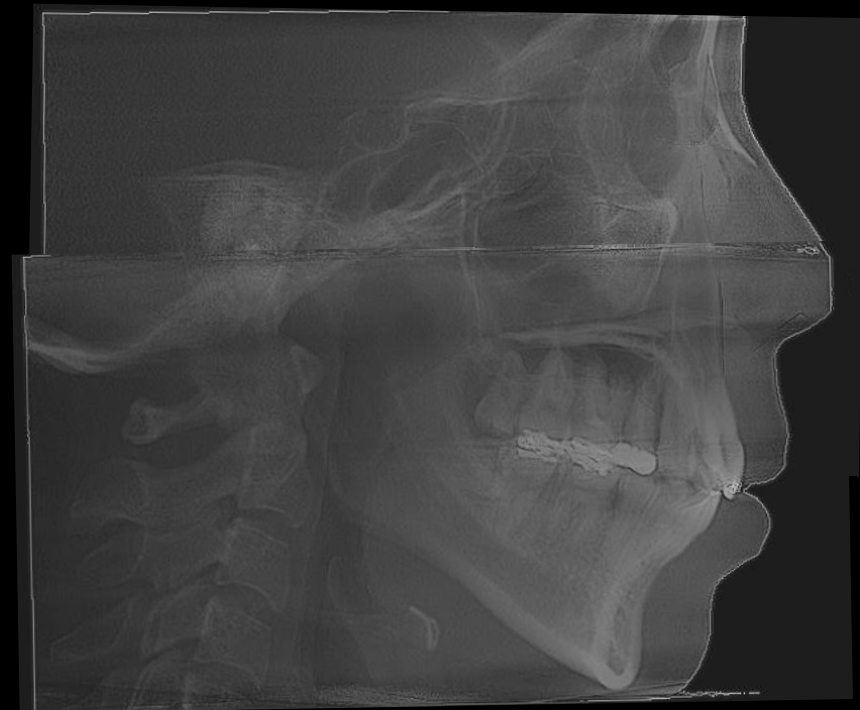
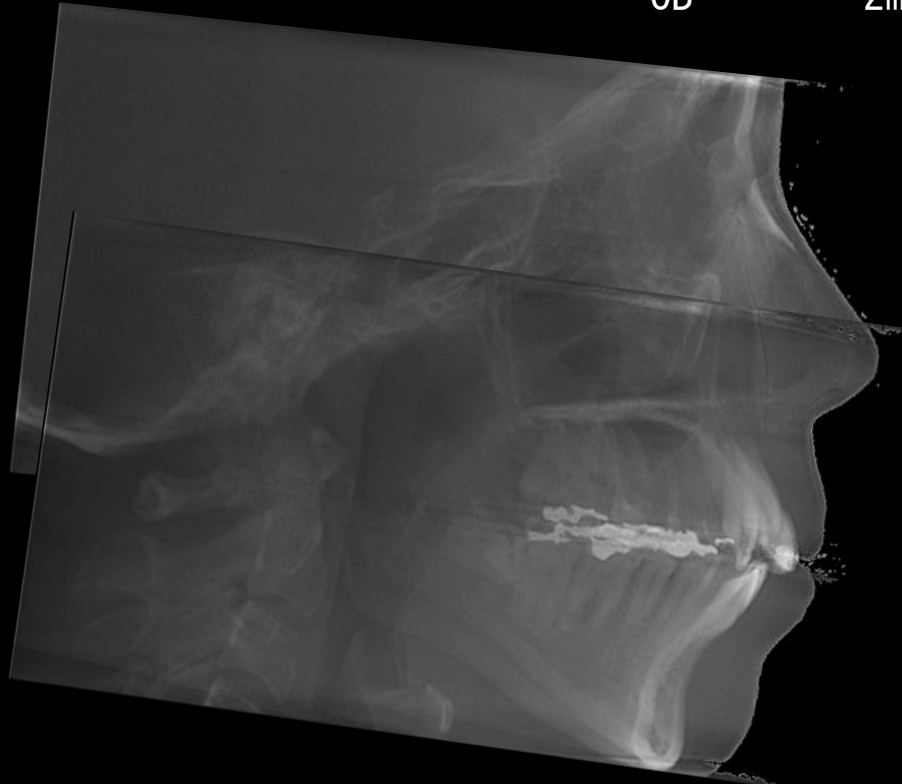
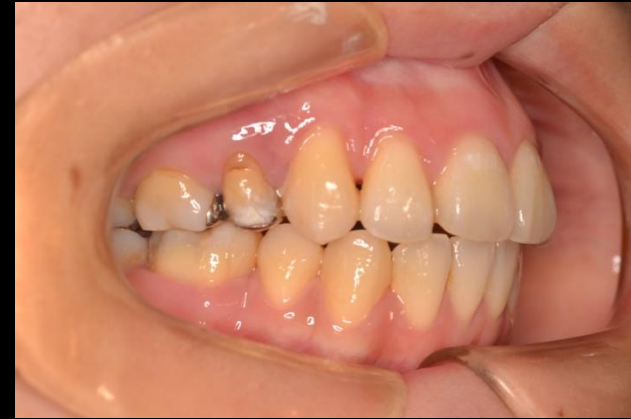
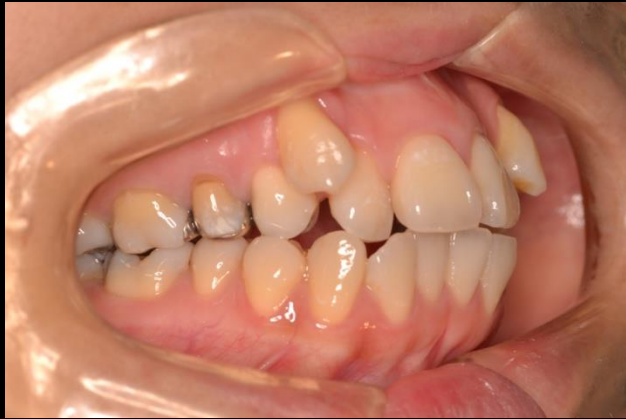
初診セファロ

術後セファロ

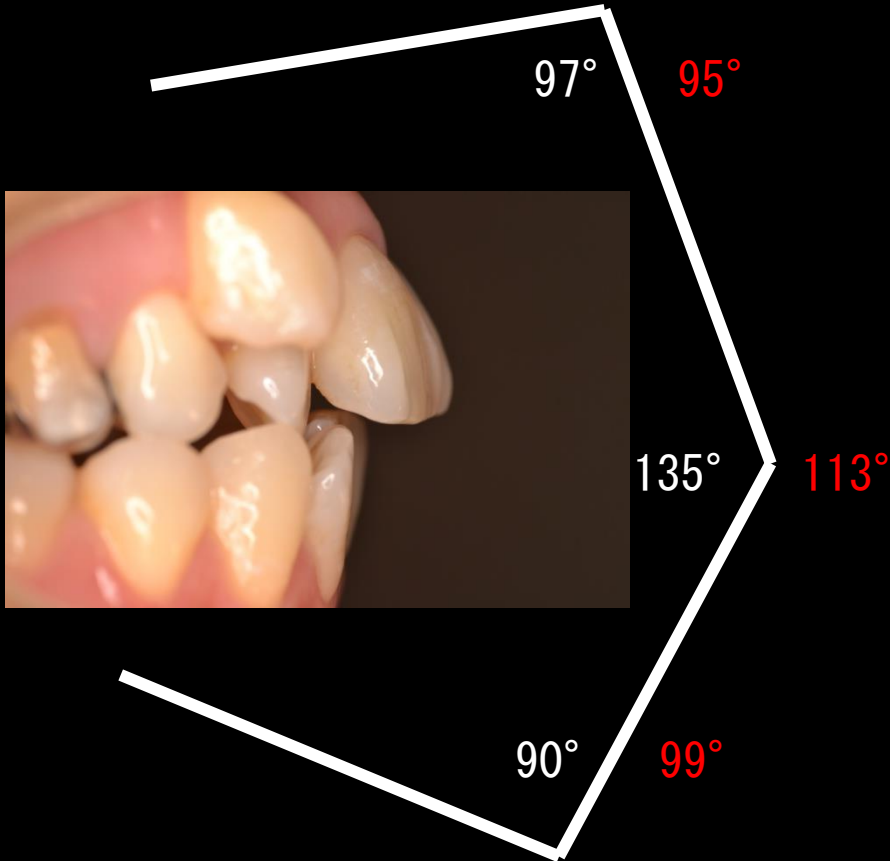
SNA 70°
SNB 64°
SN-Md 53°
U1-SN 95°
U1-L1 113°
L1-Md 99°
U1-APog 12mm
Witz -3mm
OJ 4mm
OB 2mm

SNA 71°
SNB 65°
SN-Md 53°
U1-SN 78°
U1-L1 135°
L1-Md 94°
U1-APog 7mm
Witz -3mm
OJ 2mm
OB 1mm



セファログラムの目標

術前



術後

