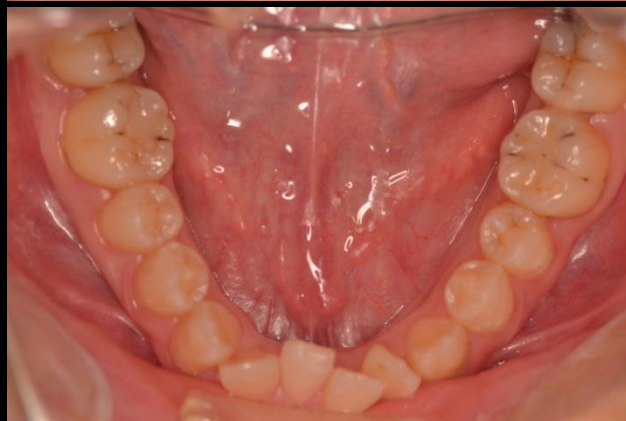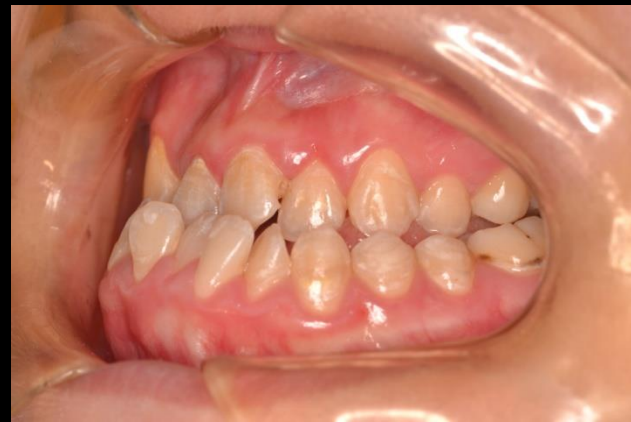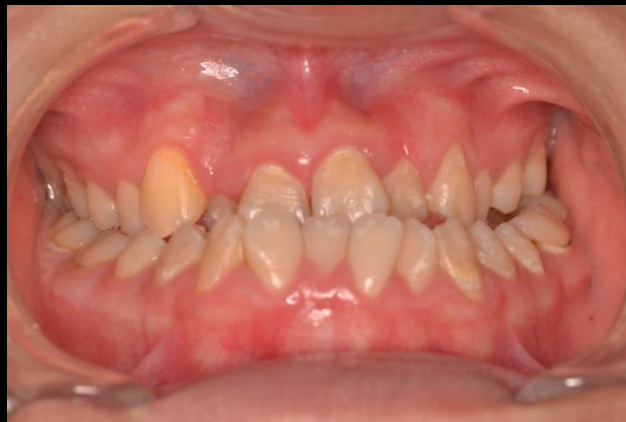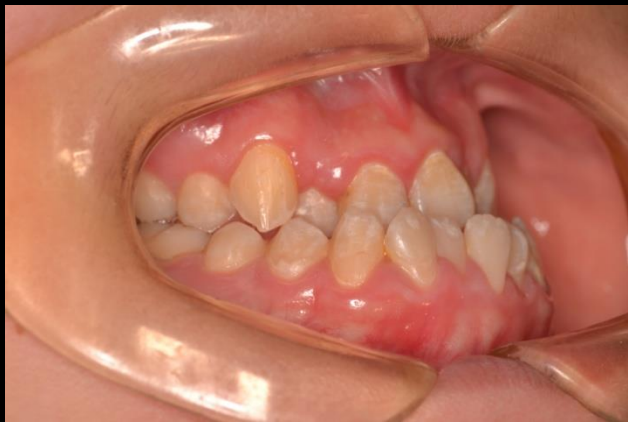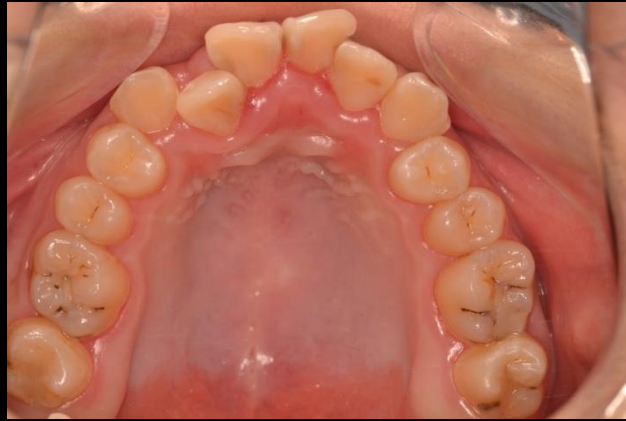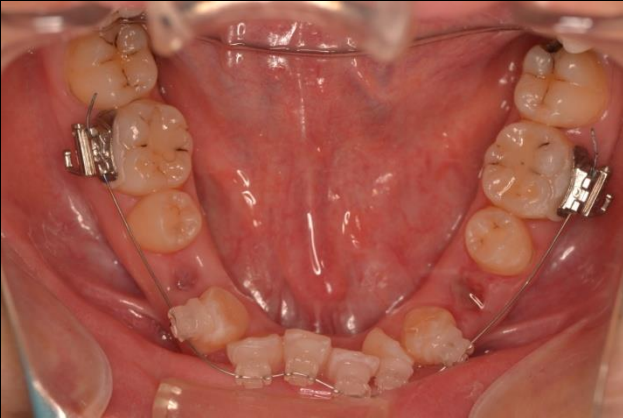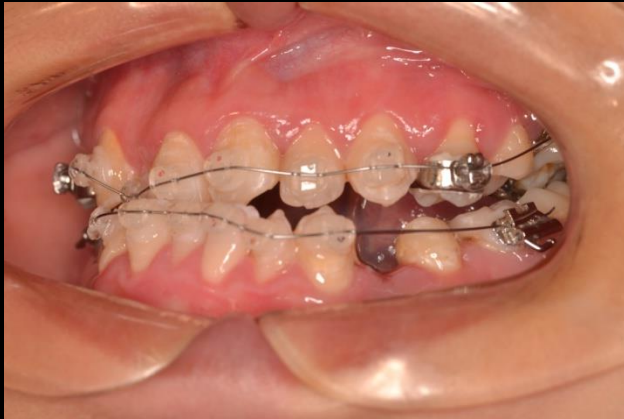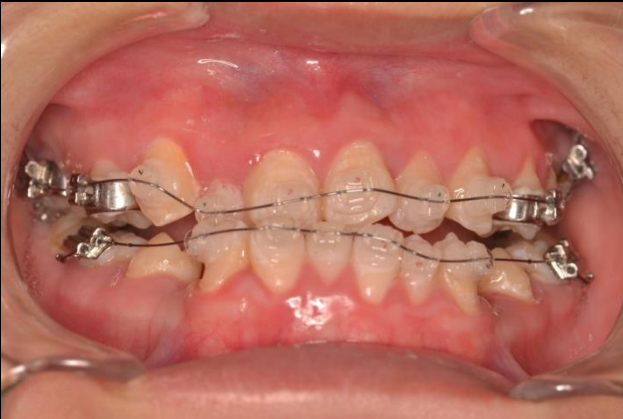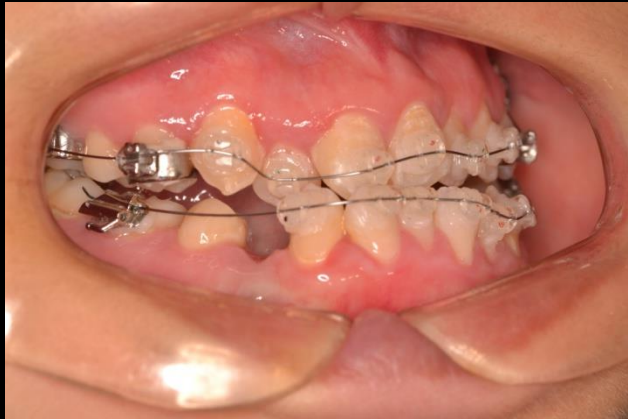
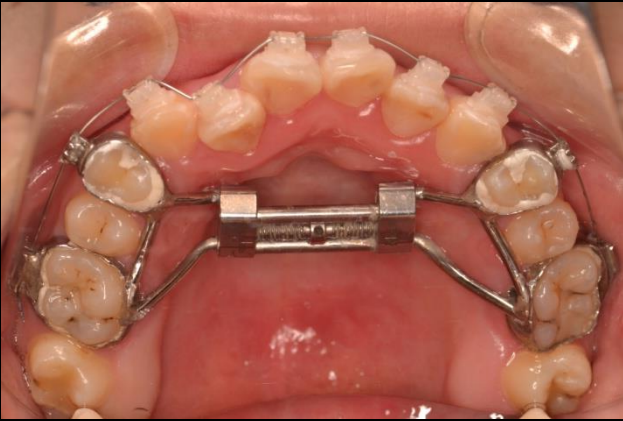


症例 3 : 14歳 女性 (反対咬合)

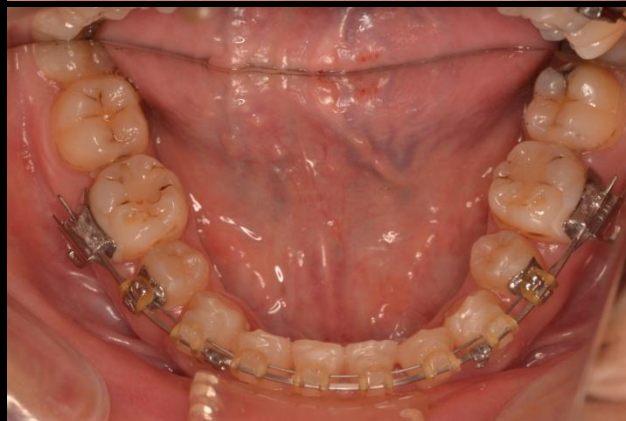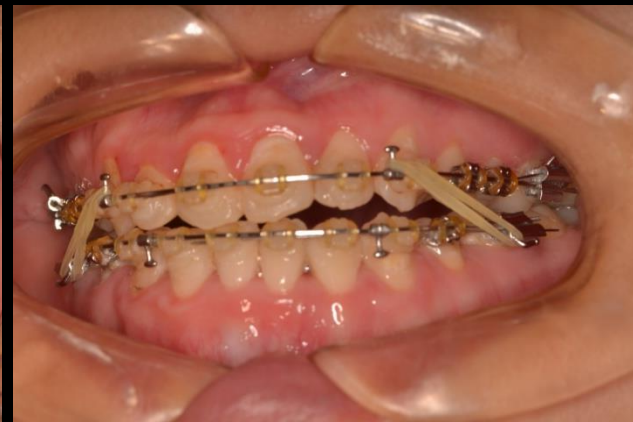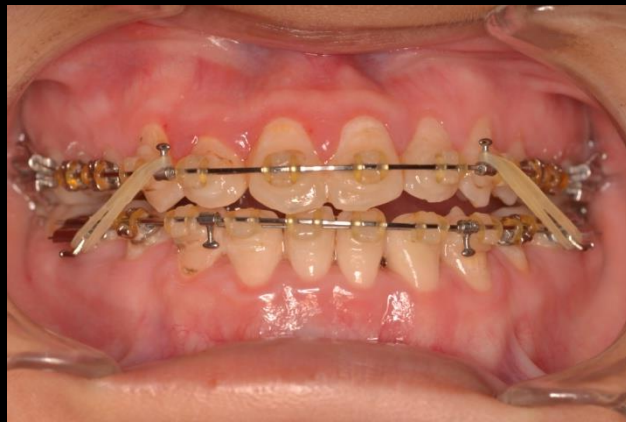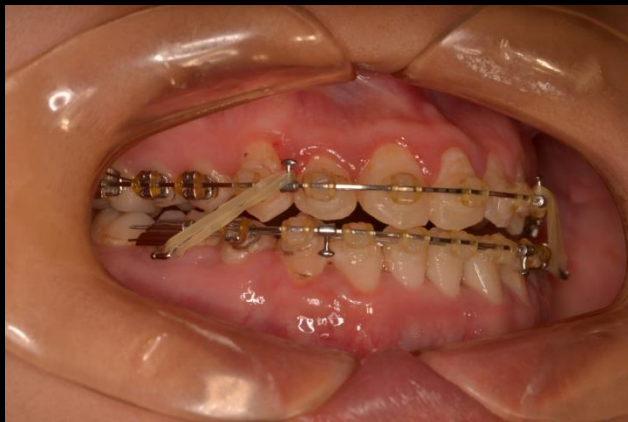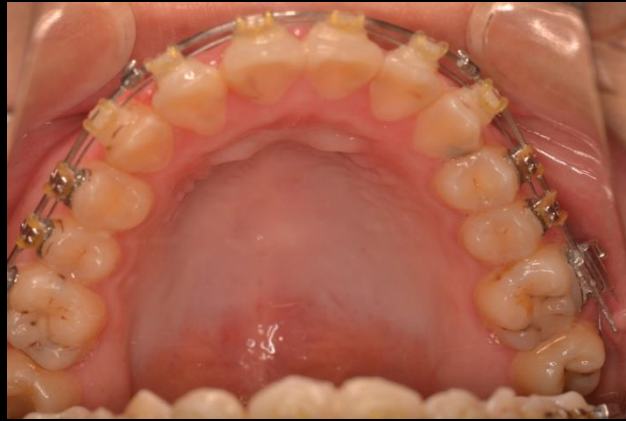初診時口腔内写真



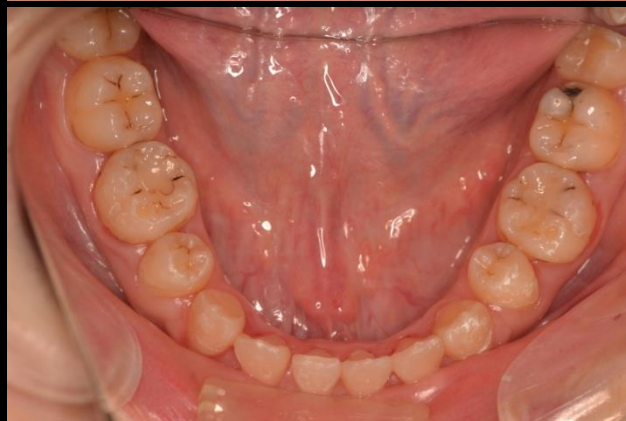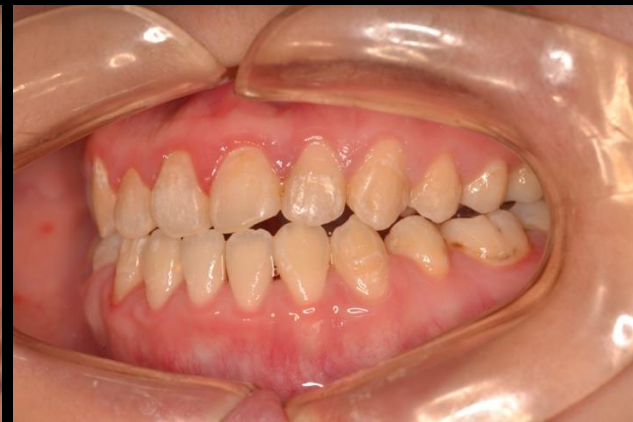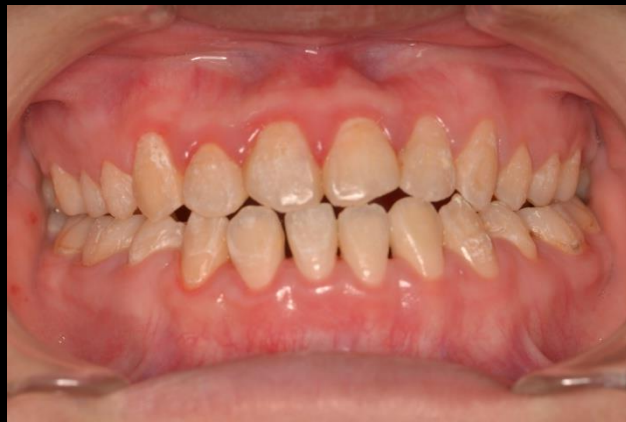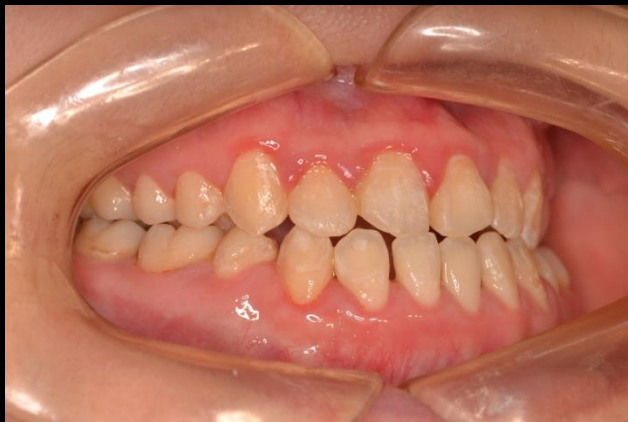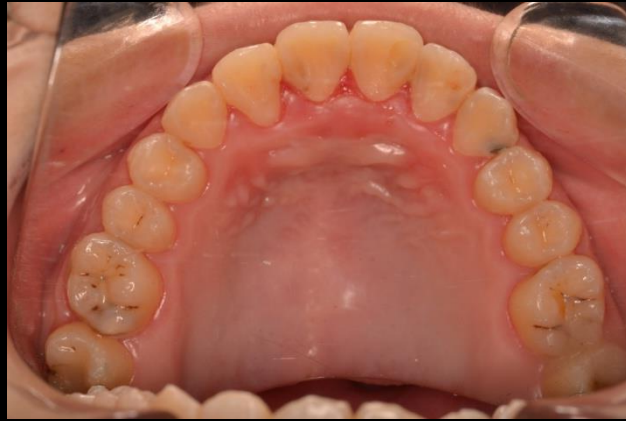Stage I Step 1 012 NiTi



Stage III



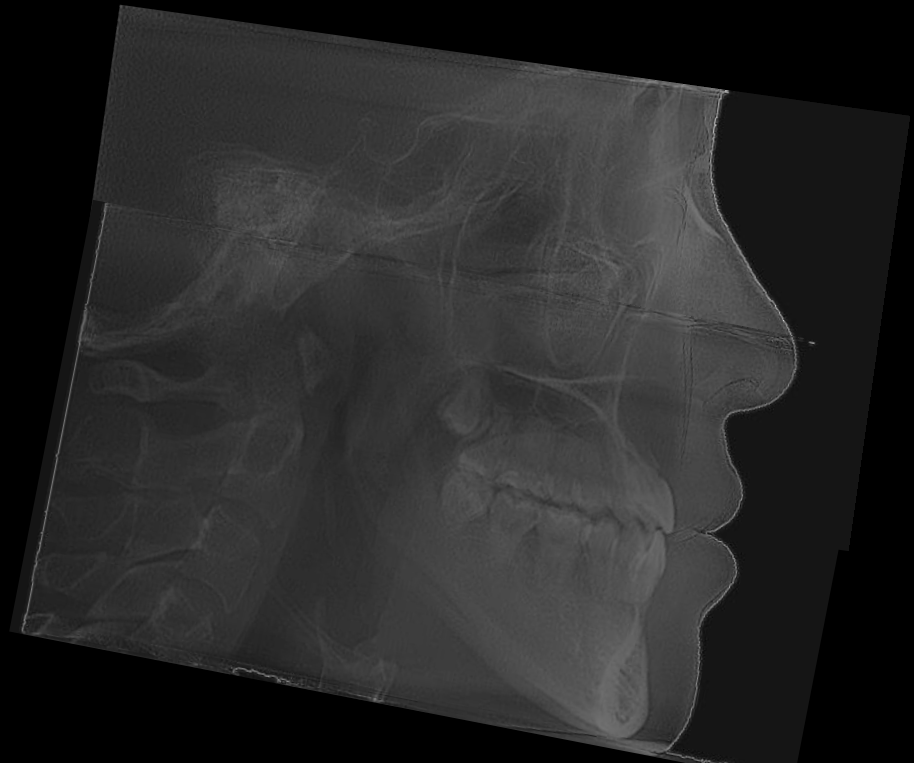
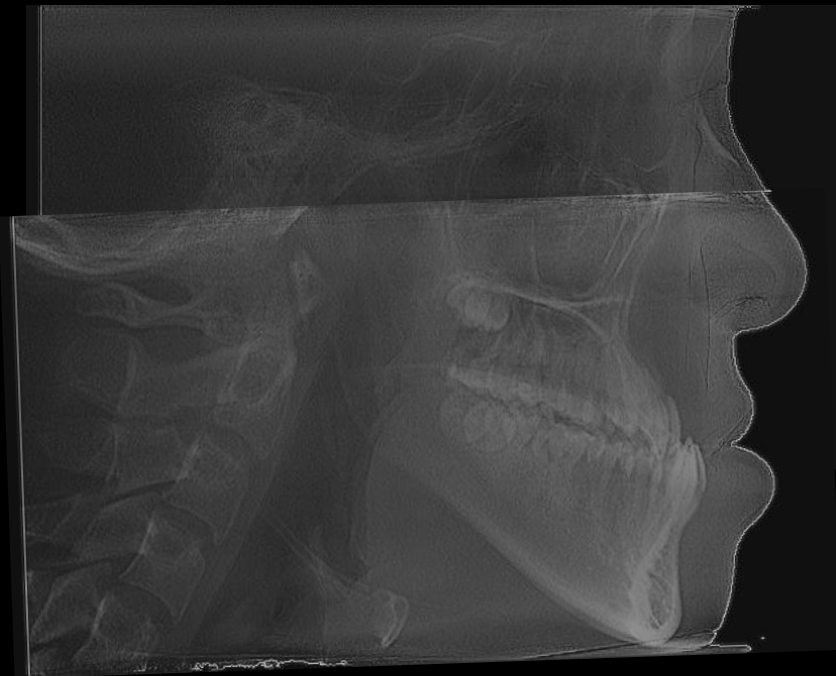
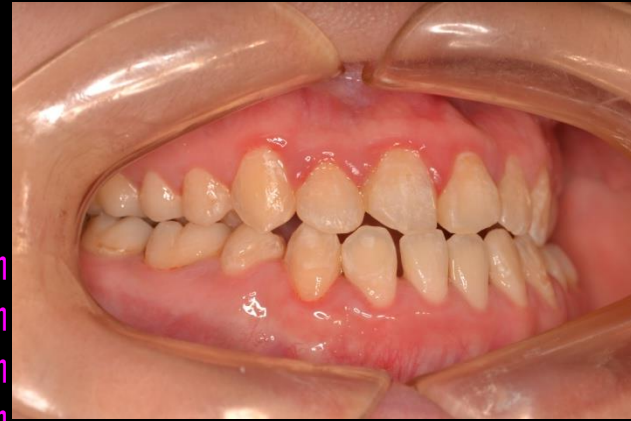矯正終了直後



初診セファロ
術後セファロ

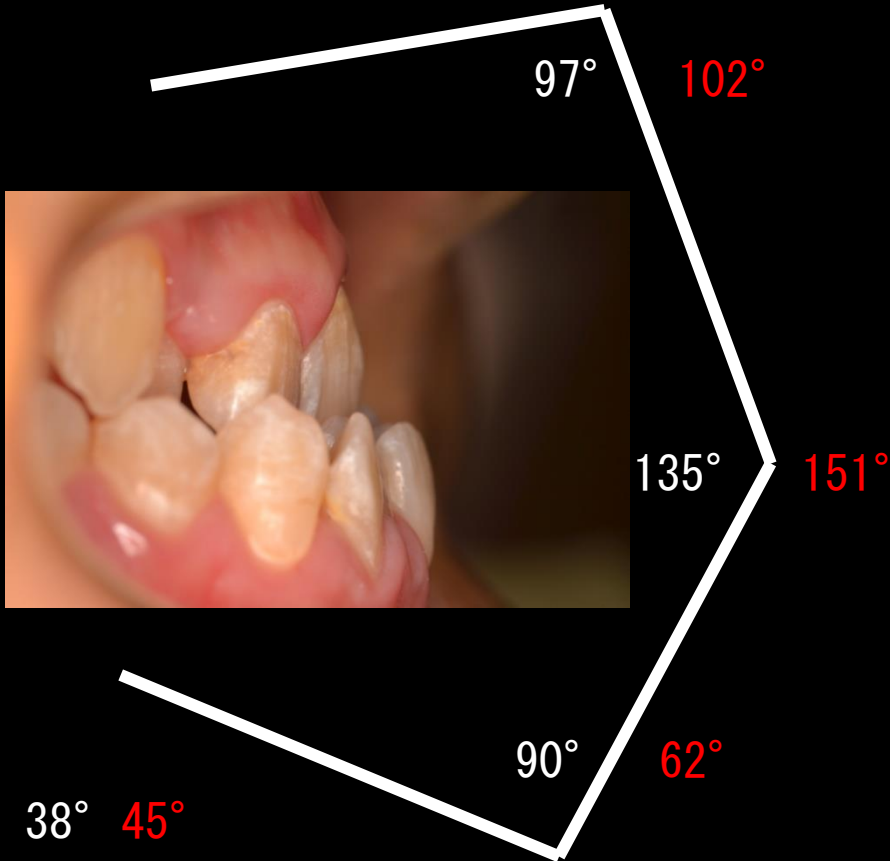
SNA 71°
SNB 80°
SN-Md 45°
U1-SN 102°
U1-L1 151°
L1-Md 62°
U1-APog 5mm
Witz -18mm
OJ -5mm
OB 4mm

SNA 71°
SNB 79°
SN-Md 50°
U1-SN 109°
U1-L1 135°
L1-Md 66°
U1-APog 9mm
Witz -16mm
OJ 2mm
OB 2mm



セファログラムの目標

術前



術後

